

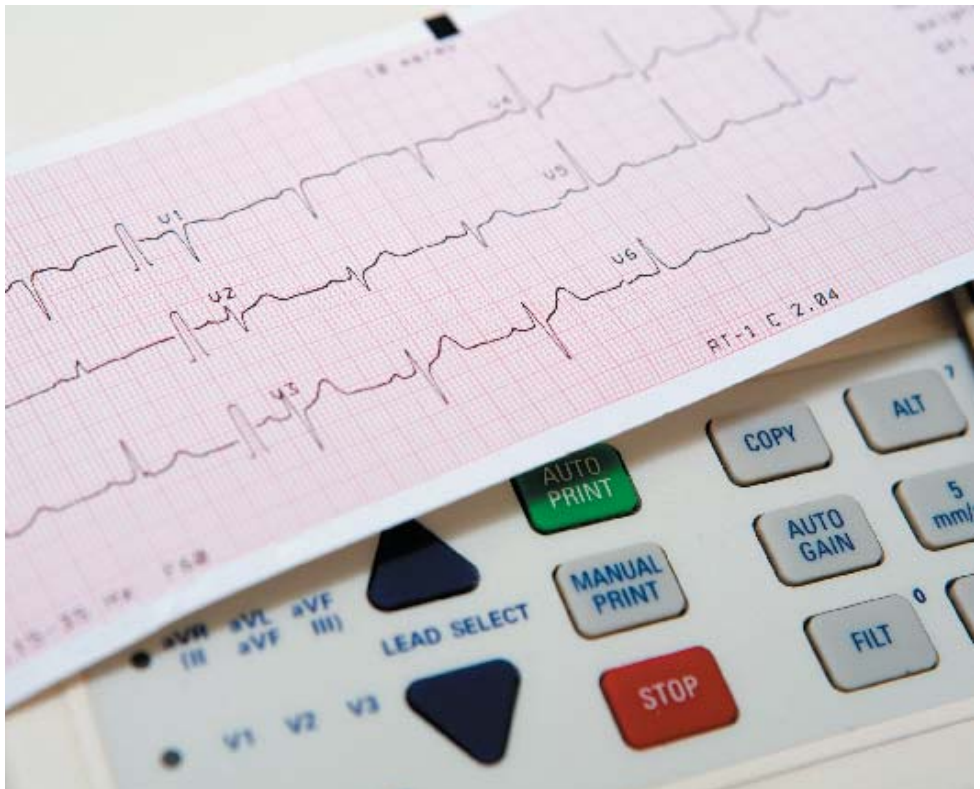

**atrialfibrillationassociation
Australia**

www.atrialfibrillation-au.org
www.afa-international.org

Providing information, support and access to
established, new or innovative treatments for Atrial Fibrillation

THE HEART, THE PULSE and THE ELECTROCARDIOGRAPH



Copyright 2011

Contents

Glossary

The Heart

The Pulse

How To Take A Pulse

The Electrocardiograph (ECG)

Further Information

Glossary

Arrhythmia

Heart rhythm disorder.

Arrhythmia Nurse Specialist

A nurse who is trained in heart rhythm disorders.

Atrial Fibrillation (AF)

An irregular heart rhythm due to a rapid, disorganised electrical disturbance of the heart's upper chambers (the atria).

Atrial Flutter (Afl)

A rhythm disorder due to a more organised electrical disturbance in the heart's upper chambers. The heart rhythm may be either regular or irregular.

Bradycardia

A rhythm disorder characterised by a slow, regular rhythm.

Cardiologist

A doctor who has specialised in the diagnosis and treatment of patients with heart conditions.

Echocardiogram

An image of the heart using echocardiography or soundwave-based technology. An echocardiogram (echo) shows a three dimensional shot of the heart.

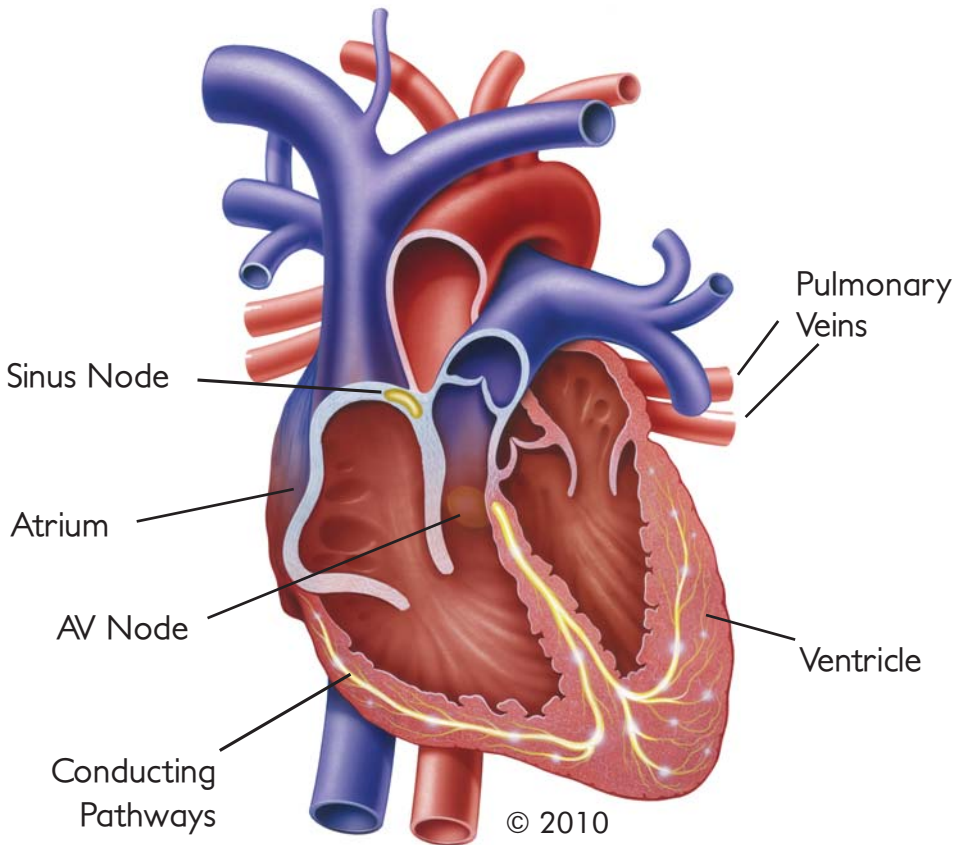
Electrocardiograph	A representation of the heart's electrical activity. An ECG is taken from electrodes on the skin surface.
Heart Failure	The inability (failure) of the heart to pump sufficient oxygenated blood around the body to meet physiological requirements.
Rhythm	The pattern of the cardiac activity. The heart has both a rate (how fast it beats) and a rhythm (the pattern of activity). Rhythm includes the ratio of atrial to ventricular activity.
Sinus Rhythm	Normal rhythm of the heart.
Syncope	Medical term for passing out from lack of oxygen going to certain areas of the brain.
Tachycardia	A rhythm disorder characterised by a rapid, regular rhythm.

The Heart

The heart is a muscular organ that generally sits in the middle of the chest, slightly towards the left and starts beating approximately 6-8 weeks after our conception. It continues this activity, beating 100,000 times a day, everyday of a person's life.

Structurally, the heart consists of two sides, a right and a left. The right side pumps the blood through the lungs to collect oxygen before travelling to the left side of the heart. From here it is pumped through the body, to return eventually to the right side once more. Both sides of the heart contract at the same time in a single coordinated action to produce a heart beat.

Each side of the heart is separated into two chambers, the atrium (upper chamber); receiving blood to the heart and the ventricle (lower chamber); pumping blood away from the heart.



The atria collect the blood from the body on the right side of the heart through a large vein called the Vena Cava and from the lungs on the left side of the heart through four Pulmonary Veins which all enter the left atrium close together. Once filled with blood, the atria contract and force the blood into the ventricles.

The atria and ventricles on both sides of the heart are separated by valves made up of thin fibrous tissue. The valve on the right side is called the tricuspid valve and the valve on the left is the mitral valve. As the ventricles contract, these valves are forced closed, preventing the backflow of blood to the atria. With the tricuspid and mitral valves closed, the blood is

pumped from the ventricles around the body, through arteries. On the right side of the heart this artery is called the pulmonary artery which takes blood to the lungs. On the left this artery, the largest artery in the body, is called the aorta.

The heart is myogenic, meaning it can initiate its own heartbeat. The sequence of events which make up a heart beat is known as the cardiac cycle.

Once filled with blood, the atria receive an electrical impulse from the sino-atrial node (SA node).

This electrical impulse spreads from the SA node over the walls of the atria and causes it to contract – forcing the blood out of the atria and into the ventricles (bottom chambers of the heart).

Whilst the ventricle is filling with blood, the impulse sent from the SA node is recognised by a second region of the heart known as the atrioventricular node (AV node). The AV node then sends its own electrical impulse over the walls of the ventricle, causing blood to get pumped around the body.

Because the sino-atrial node (SA node) controls and coordinates the heart beat, the natural heart rhythm is known as ‘sinus rhythm’.

The pumping action of the heart must allow time for the blood to move from the upper chambers to the lower chambers and then out into the rest of the body. If the heart goes too slowly (Bradycardia) then the output of blood can be insufficient to supply the body’s needs. Bradycardia can make someone feel light-headed or tired.

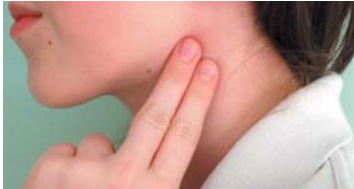If the heart goes too rapidly and there is not enough time for the bottom chambers to fill up properly, then, once again, the output of blood can be insufficient to supply the body’s needs. In this case you can feel tired and breathless as the body’s demands are larger than the supply.

For patients diagnosed with Atrial Fibrillation the Sinus Node no longer controls the rhythm of the heart. Many different parts of the atrial chamber contract at many different times. This makes the contraction of the upper chambers disorganised and ineffective. It is important to note that while the atrial contraction has some impact on the hearts action as a pump the majority of the flow into the ventricle is passive and so patients who are in AF need not be unduly concerned about problems arising due to the atria contractions being interrupted.

The Pulse

The pulse indicates the heart rate and the heart rhythm. Being aware of your pulse is important because it may indicate an abnormal heart rate or rhythm. The pulse can be taken in several points on your body, two of the easiest places are:

On the neck: below the earlobe between the muscle of the neck and the wind pipe (carotid pulse)



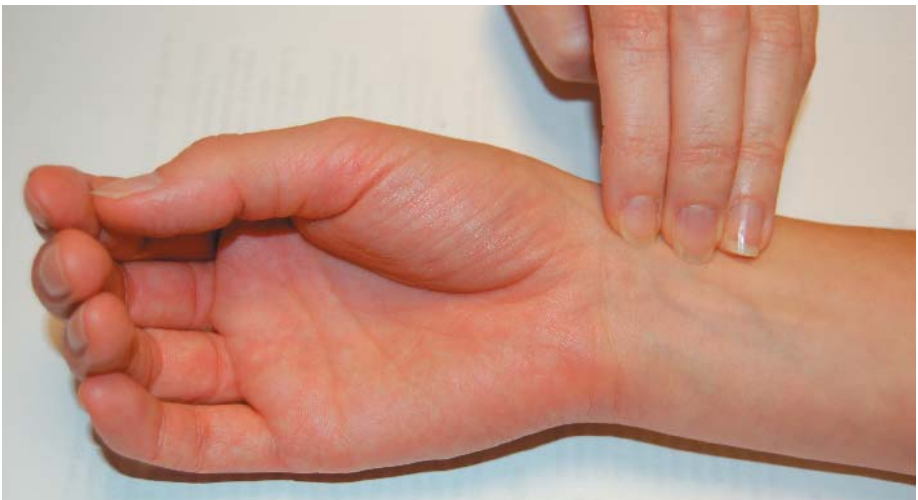
On the wrist: between the end of the thumb and where a watch strap would rest (radial pulse)



In a First Aid situation, the pulse lets you know if the heart is beating. Ideally it should beat in a rhythm, like the ticking of a clock; occasionally it may miss a beat, but in general, this is normal. However, if your pulse has no pattern, then it is said to be irregular and should be checked by your doctor.

How To Take A Pulse

Taking A Pulse: The easiest way to detect Atrial Fibrillation



- ♥ Using three fingers, place them on the inside of the wrist between the watch strap and the base of the thumb.
- ♥ Keep firm pressure on the wrist with your fingers in order to feel the pulse.
- ♥ The rate of the pulse can be found by counting for a minimum of 15 seconds and multiplying by four, better 30 seconds and multiplying by two, this can give the number of beats per minute (bpm).
- ♥ The heart rate naturally varies, depending on activity and time of day.

The pulse should have the rhythm of a ticking clock.

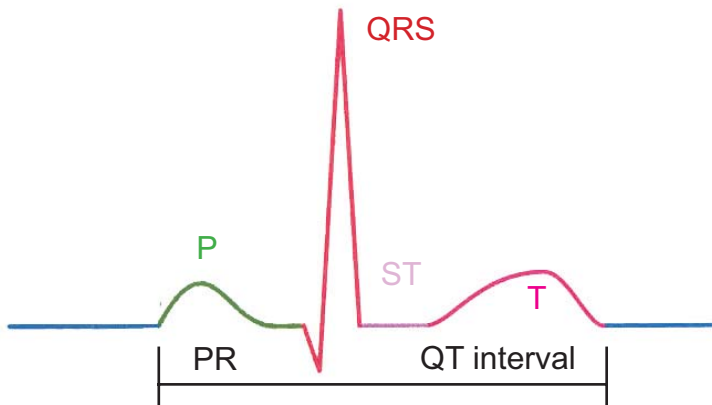
The Electrocardiograph (ECG)

Although it was shown in 1774 that an electric current could restore life in the presumed dead, similar to the shocks given in advanced first aid, it took a further one hundred years before Carlo Matteucci, Professor of Physics at the University of Pisa, could show that each heart beat generated an electrical current. In 1887, British physiologist Augustus D. Waller of St Mary's Medical School, published the first human electrocardiogram, recorded from Thomas Goswell, a technician in the laboratory.

Since this time, the ECG has been developed and refined to become one of the most important aspects into the investigation of the patient with possible heart related problems. Its spiked graph-like appearance has become an icon of the medical profession, yet is still poorly understood by the general population.

When interpreting an ECG, it is important to remember that the contraction of each muscle cell of the heart, generates a small electrical impulse. It is the recording of these impulses, together through receptors placed on the skin, that the ECG pattern is generated.

The components of the ECG are labelled P, QRS and T waves. These parts of the pattern show the different parts of the cardiac cycle.



The P Wave shows the conduction of the atria and gives a small humped feature. Many clinicians talk about this being the ‘trigger’ of the heart beat when discussing this with their patients. People who have or experience Atrial Fibrillation at the time of the ECG being performed, will not have co-ordinated contraction of the atrial muscle cells; thus the P wave would be missing.

The next point of interest is termed the PR interval. This is the delay caused as the heart’s impulse passes from the SA node, across the atria walls and AV node. In the heart’s contraction this allows the time for blood to pass from the atrial chamber to the ventricle, on the ECG trace this is shown as a gap between the P wave and the sharp peak of the QRS sequence.

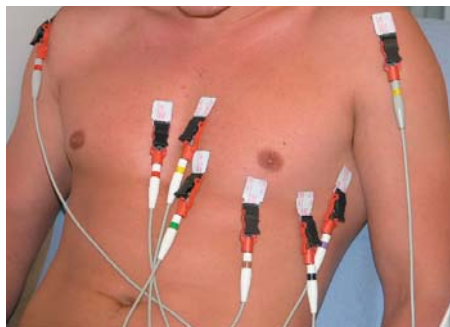
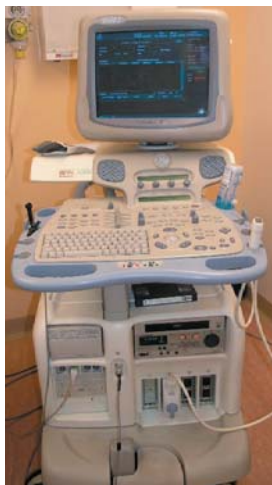The classical sharp peak of the ECG is termed the QRS complex. This shows the electrical impulse moving very rapidly through the AV node and flowing through the ventricles causing them to contract and pump the blood out of the heart to form the pulse.

Following the QRS complex the ECG becomes quiet again with a short flat line from the final part of the QRS complex (the S wave) and the following wave (the T wave). This section is called the ST segment. This is demonstrating the pause after the muscle cells have contracted.

In patients who take digoxin for their Atrial Fibrillation this portion of the ECG can change shape. If the heart rate is acceptable this simple change is unimportant but may receive comment from the clinician.

The final portion of the ECG complex is the T wave, this small bump in the pattern shows the heart cells all returning to their relaxed state, preparing for the next contraction to be triggered.

To record an ECG, wires are attached to the body, usually on the arms, legs and across the chest. These detect the small electrical impulses as described earlier.



From the twelve leads, the ECG shows different views of the electrical activity of the heart.

To the skilled eye the arrangement and shape of the various components of the ECG are viewed as a functioning heart. In certain arrangements these are clearly a normal pattern, with many variations of normal. Other times the pattern clearly shows abnormality. Unfortunately for the clinician there is the middle ground where the ECG can look abnormal but be acceptable for that individual. Interpretation of the ECG could be likened to a photographer taking a 3D electrical photograph of the heart and it helps the clinicians to identify the possible source of a problem.

In people suffering from Paroxysmal Atrial Fibrillation the ECG can look completely normal in between episodes (paroxysms) of Atrial Fibrillation.

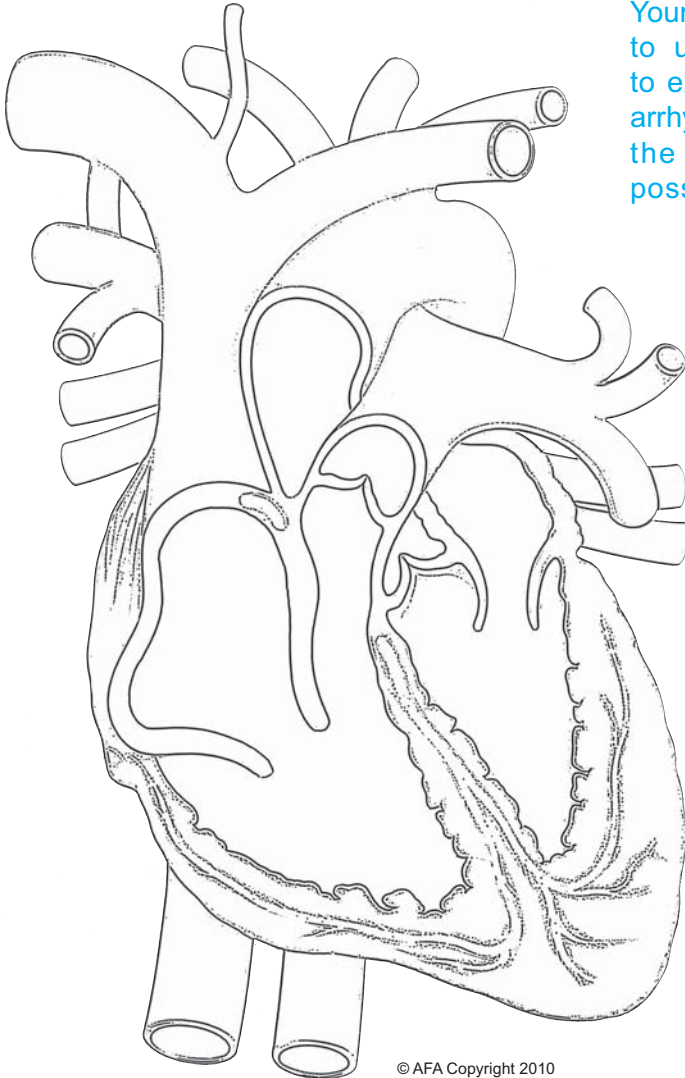
People who have cardiac problems (for example, Atrial Fibrillation) can find they are frequently asked to have ECGs performed. In this situation each subsequent recording can be compared back to other tracings on record to look for changes and concerns in the ongoing management of the heart problem.

Further information

Helpline: 1800 050 267 or (02) 61084602

Email: Info@atrial-fibrillation-au.org

Website: www.atrialfibrillation-au.org



Your doctor may wish to use this diagram to explain a detected arrhythmia or illustrate the actions of a possible treatment.



Atrial Fibrillation Association

MEMBERSHIP APPLICATION

Register to become a member of AFA Australia on line at
www.atrialfibrillation-au.org
www.afa-international.org

**This booklet has been adapted for AFA Australia
with kind permission from the Atrial Fibrillation Association
www.afa.org.uk**

AFA Medical Advisory Committee:

Dr Michael Davis
Professor Ben Freedman
Dr Gerry Kaye

Director & Chief Executive:

Mrs Trudie Lobban

Assistant Director:

Mrs Jo Jerrome

Please remember these are general guidelines and individuals should always discuss their condition with their own doctor.



**atrialfibrillationassociation
Australia**

www.atrialfibrillation-au.org
www.afa-international.org


Arrhythmia Alliance
The Heart Rhythm Charity
Affiliated to Arrhythmia Alliance
www.heartrhythmcharity.org.uk

A branch of
AFA International

atrialfibrillationassociation
www.afa-international.org